DISEASES OF THE LACRIMAL SYSTEM AND ORBIT I

BY: DR. E. M. NYENZE

DATE: 10th/April/2017

INTRODUCTION

- *Most important condition: epiphora secondary to blockage in the lachrymal system.*

ANATOMY OF LACRIMAL SYSTEM

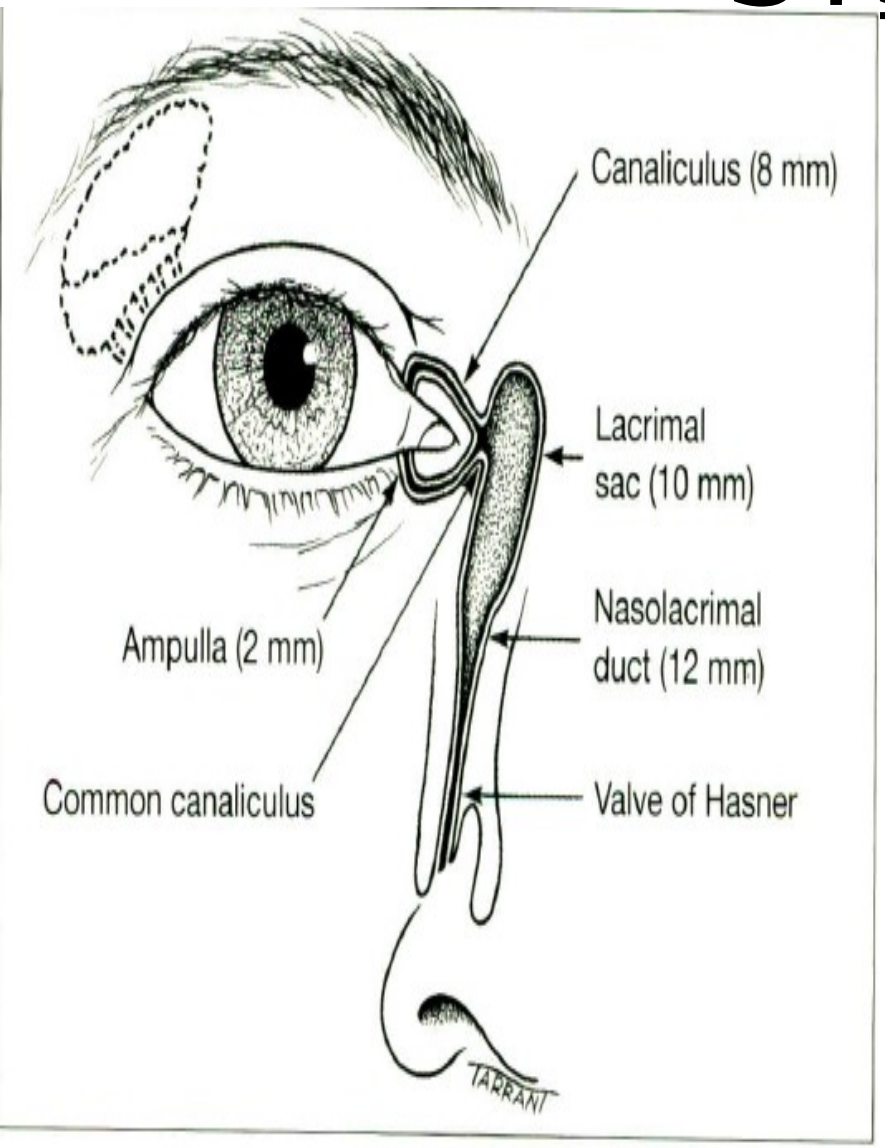

- *The lachrymal system is made of the production system and the drainage system*
- *Main lachrymal sac is in the supero – temporal aspect of the orbit*
- *From lachrymal gland → conjunctival cul de sac*
- *On blinking → puncta → canaliculi → lacrimal sac → nasolacrimal duct → inferior meatus behind the nose*

THE TEAR FILM

- *A new tear film is created every time one blinks.*

1. *1st layer: mucous layer produced by goblet cells*
   - *Makes the corneal surface hydrophilic*
2. *2nd layer: aqueous layer produced by the main lacrimal gland*
3. *3rd layer: lipid layer prevents evaporation and is produced by the meibomian glands.*

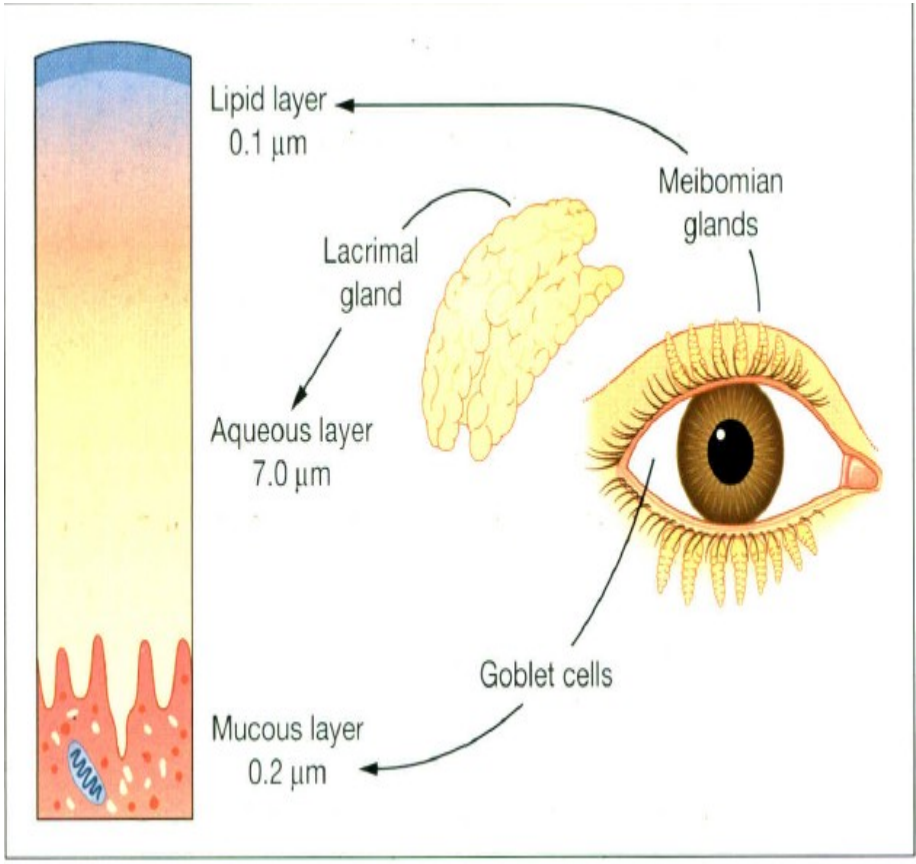

DRY EYE SYNDROME

Functions of the tear film

- *Provides oxygen to the corneal epithelium*
- *Anti-bacterial effect with IgA, lactoferrin and lysozyme*
- *Making the corneal surface optically smooth*
- *To wash away debris, dust*

CAUSES OF DRY EYE SYNDROME/ KERATOCONJUNCTIVITIS SICCA

- *Sjogrens syndrome: associated with dryness of the mouth and connective tissue disorders*
- *Meibomian dysfunction: the lipid layer production is hindered*
- *Destruction of lacrimal gland: e.g. surgical or radio - therapeutically; the aqueous layer production is hindered*
- *Lagophthalmos: formation of a tear film is prevented*
- *Conjunctival scarring: goblet cell destruction*
- *Old age: tear production is reduced in old age*
- *Defective blinking*

SYMPTOMS

- *Foreign body sensation (Esp. after wind has blown)*
- *Dryness/ grittiness of eyes*
- *Photophobia: the biggest function of tears is to make the corneal surface optically smooth*
- *Blurred vision*
- *Itchiness*
- *Redness of eyes*
- *Reflex excessive tearing:*
  - *The patient has a dry eye → irritation → excessive reflex tearing*
- *Whitish frothy discharge at the corner of the eye*

SIGNS

- *Blepharitis: eye lid inflammation with swelling*
- *Epithelial erosions staining with fluorescein*
- *Unstable tear film*
- *Debri/ mucus plagues/ filaments staining with rose bengal*
- *Conjunctival injection*
- *Low tear film height*

INVESTIGATION OF EYE DRYNESS

- *Staining tear film with fluorescein/ rose bengal*
- *Tear film height*
- *Tear break up time*
- *Schirmir's test:*
  - *Tells how much tears are produced*
  - *A filter (Schirmir's) paper is laced in the eye*
  - *The tears should go up to 10mm in 3 minutes*

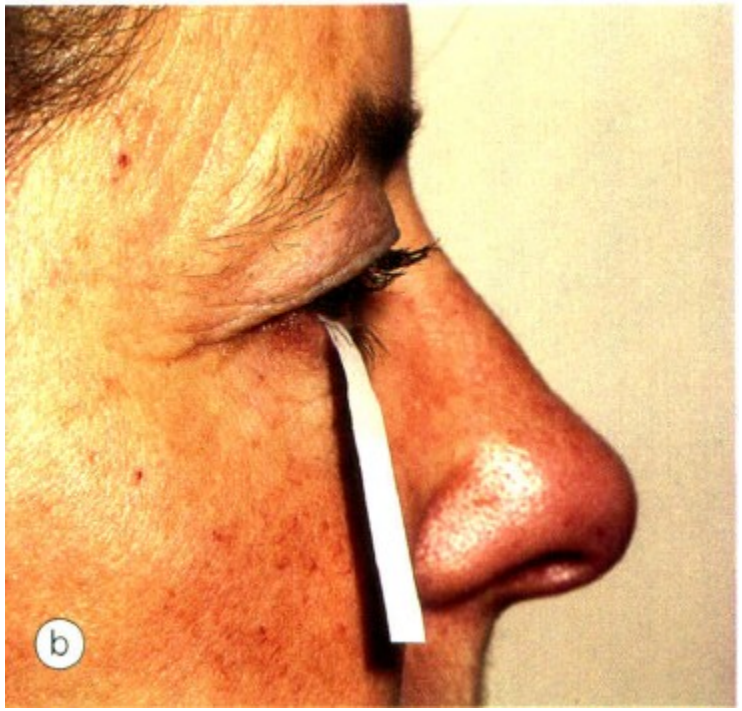

TREATMENT

- *Conservative:*
  - *Avoid enviromental trigers, avoid prolonged computer use etc.*
- *Medical:*
  - *Tear substitues (artificial tears), anti-inflammatory drops*
- *Surgical:*
  - *Punctal occlusion (cauterization or plugging)*

EPIPHORA

- *This is excessive tearing due to an obstructive cause (poor drainage), flowing down the cheeks.*

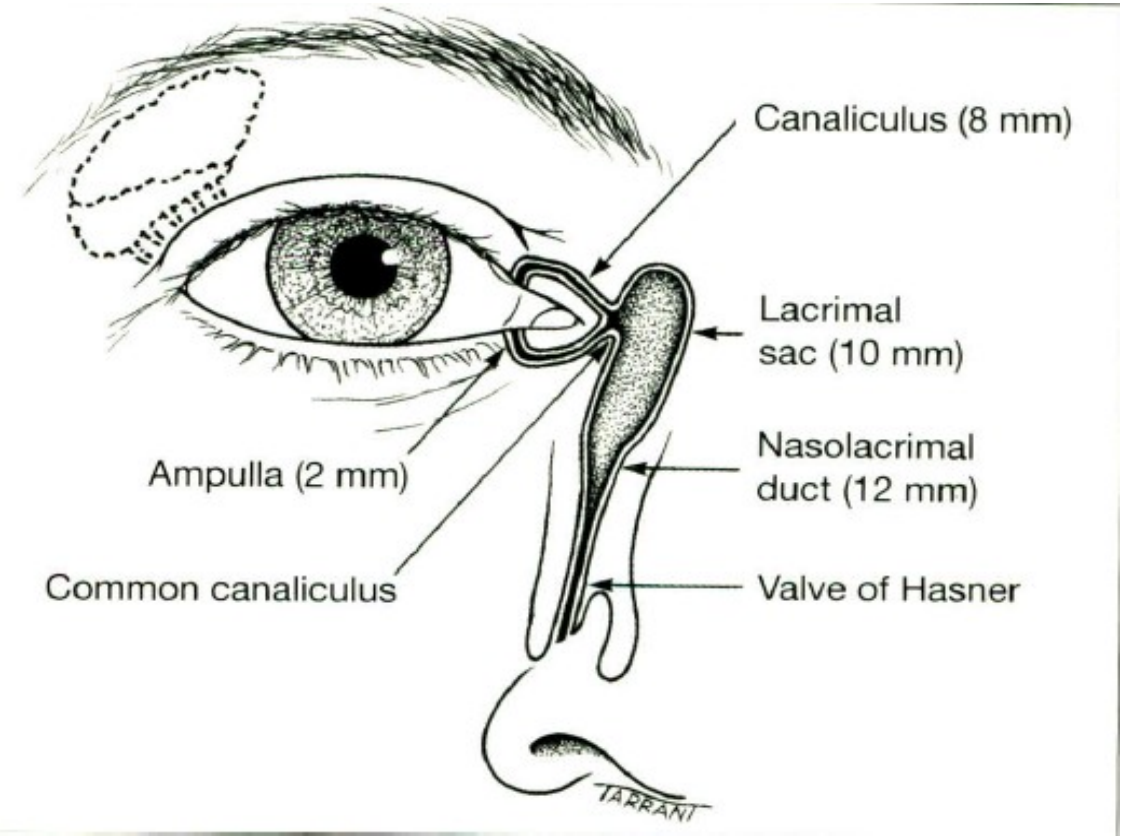

CAUSES

- *Defective drainage:*
  - *Obstruction of drainage system*
  - *Malposition of punctum*
- *Defective lacrimal pump e.g. facial nerve palsy*
- *NOTE: Hyper - lacrimation, due to hyper - secretion from irritation is NOT considered true epiphora*

EVALUATION

- *Rule out hyper – lacrimation e.g. 2^0 to infection, irritation, FB sensation*
- *Inspection:*
  - *Cause of irritation*
  - *Eye lid malpositioning tearing*
- *Syringing (put cannula and push water through the puncta)*
  - *This is the best way of diagnosing obstruction in the lachrymal drainage system*
- *Dye disappearance test*
- *Jones dye tests*

ACQUIRED OBSTRUCTION OF DRAINAGE SYSTEM

- *Puntal stenosis/ atresia*
- *Cannalicular stenosis/atresia*
- *Naso - lacrimal duct obstruction*

TREATMENT

- *Observe if not severe*
- *Punctal dilatation if stenosed*
- *Dacro - cystorhinostomy (DCR) in severe of nasolacrimal duct obstruction*

CONGENITAL NASOLACRIMAL DUCT OBSTRUCTION

- *Presents with tearing from birth*
- *Also has matting of lashes, frequent discharge, reflux on pressure over lacrimal region*
- *Misnomer*
  - *Nasolacrimal duct obstruction occurs more proximally*
  - *It is also permanent unlike failure of canalizationof the valve of Hasner*
- *Caused by delayed canalization of distal part of nasolacrimal duct (valve of Hasner)*
  - *Valve of Hasner prevents the air from going up the nasolacrimal duct*

TREATMENT

- *Most of the cases resolve spontaneously before the first birthday*
- *Massage over lacrimal sac area can help open up*
- *Frequent secondary infections can be treated with antibiotics*
- *Therapeutic probing and syringing (under GA) is done if problem persists beyond one year of age.*

ORBIT I

ANATOMY OF THE ORBIT

RELATIONS OF THE ORBIT

- *Medial wall: nasal cavity, ethmoidal air cells, sphenoid sinus*
- *Lateral wall: middle cranial, temporal and pterygopalatine fossae*
- *Roof: anterior cranial fossa frontal sinus and supra orbital notch*
- *Floor: maxillary sinus and palatine air cells*

SURROUNDING SINUSES

CLINICAL EVALUATION OF ORBITAL DISEASE

- *History: pain, mode of onset, trauma, associated symptoms e.g. dystopia, proptosis (NB, the MC cause of proptosis worldwide is thyroid orbitopathy)*
- *General exam*
- *Optic nerve function tests*
  1. *Visual acuity*
     - *If reduced optic nerve compression, exposure keratopathy*
  2. *Color vision (red vs. green)*
  3. *Pupillary reflexes (afferent pathway optic nerve)*
  4. *Vision scan*
  5. *Contrast sensitivity*
- *Inspection*
- *Ocular motility*
- *Ocular exam: conjunctiva, cornea, pupil, fundus*

CONT.

- *Measure amount of proptosis (Hertel's exophthalmometer, clear plastic ruler)*
- *Palpate*
- *Auscultate*

THE 7 Ps OF ECALUATION OF ORBITAL DISEASES

- *Pain*
  - *Painful: infection, inflammation, malignancy*
  - *Painless: thyroid orbitopathy, vascular malformations*
- *Proptosis*
  - *severe: over short period: inflammatory, malignancy*
  - *Chronic: malignancy*
  - *Dystopia: if inferior □ lesion is superior; if lateral □ lesion is medial*
- *Progression*
- *Palpation*
  - *Mass? Consistency? Fluctuant? Tender? Measurement?*
- *Pulsation*
  - *Pulsatile: vascular malformations (AVM)*
- *Peri – orbital changes*
  - *Ecchymosis: hemorrhage*
  - *Darkening: chronic*
  - *Shiny surface: inflammation*
  - *Pus: suppuration*
- *Pupil*
  - *Pupillary reflexes*

ORBITAL TUMORS

VASCULAR TUMORS/MALFORMATONS

- Capillary haemangiomas
- Cavenous haemangiomas
- Orbital varices
- AV Malformations
- Lymphangiomas
- Haemangiopericytomas

Nero tumours

- Optic nerve gliomas
- Meningiomas
- Schwanomas
- neurofibromas

Muscular tumors

- Leimyomas
- Rhabdomyosarcomas

(does not originate from extraocular muscle)

Orbital fat tumors

- Lipomas
- Atypical lipoma
- sarcomas

Bony masses

- Oteomas
- Chondromas
- Fibrous dysplasias
- Osteosarcoma
- Ewings sarcoma

others

- Metastatic tumors- neuroblastoma, ca breast
- Orbital cysts
- Orbital pseudotumors
- Sino nasal tumors extending to orbit